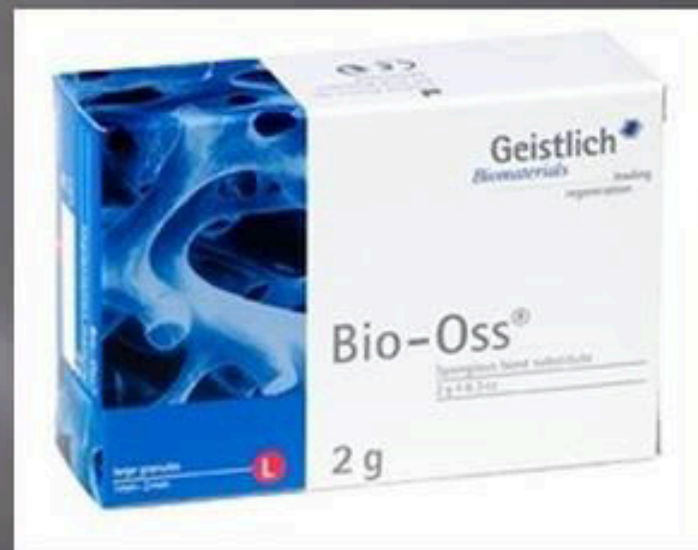
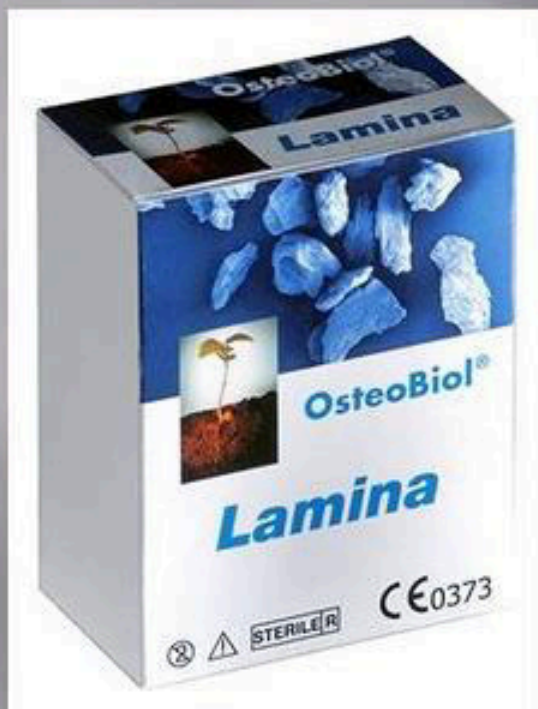
# Method of semi-hard frame OsteoBiol

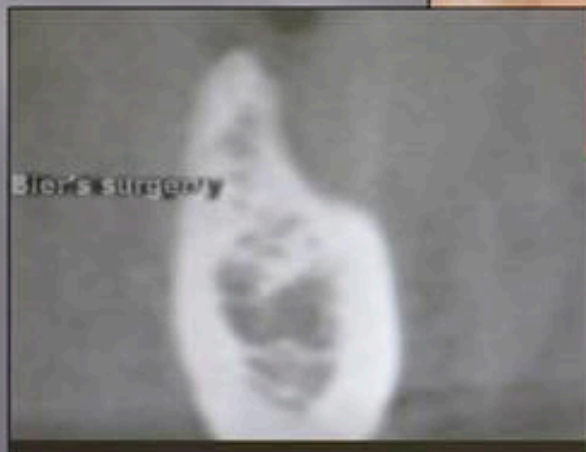
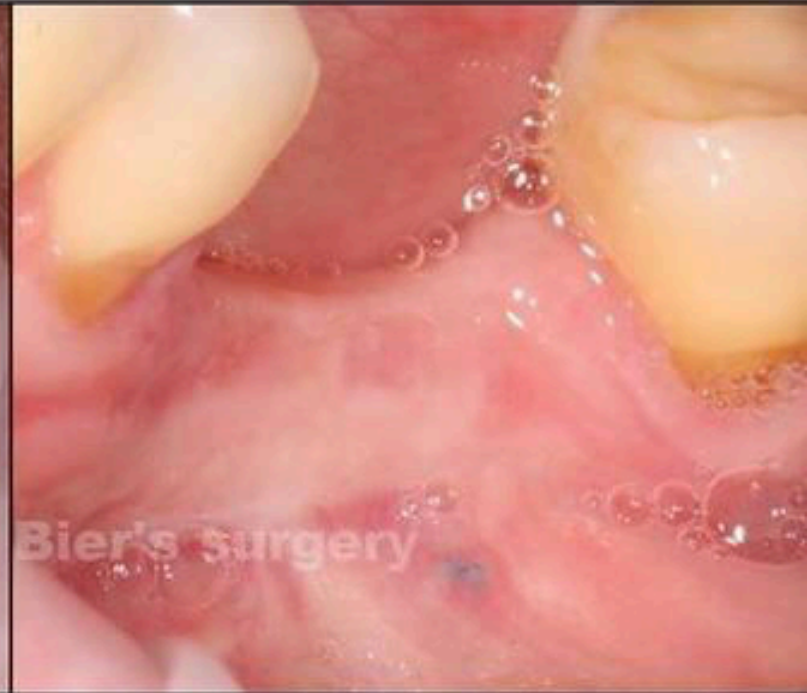
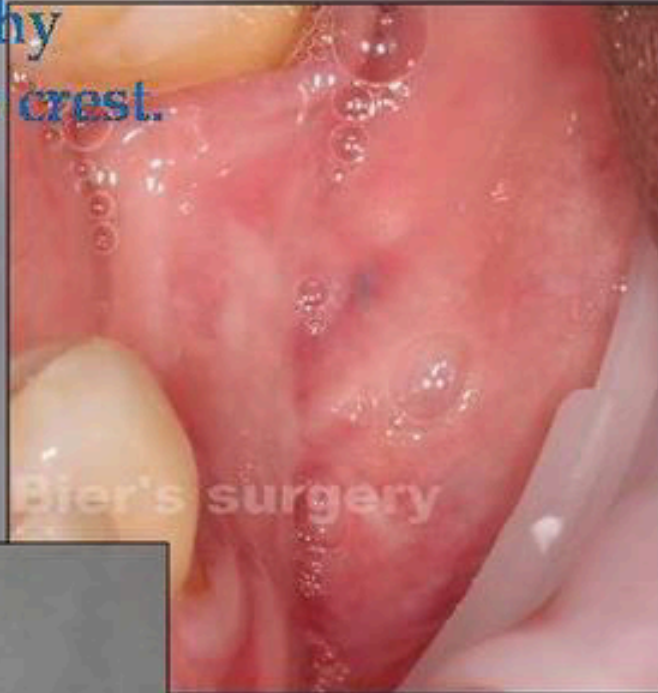Хирург-имплантолог  
Пономарев О.Ю.

<http://olegponomarev.ru>

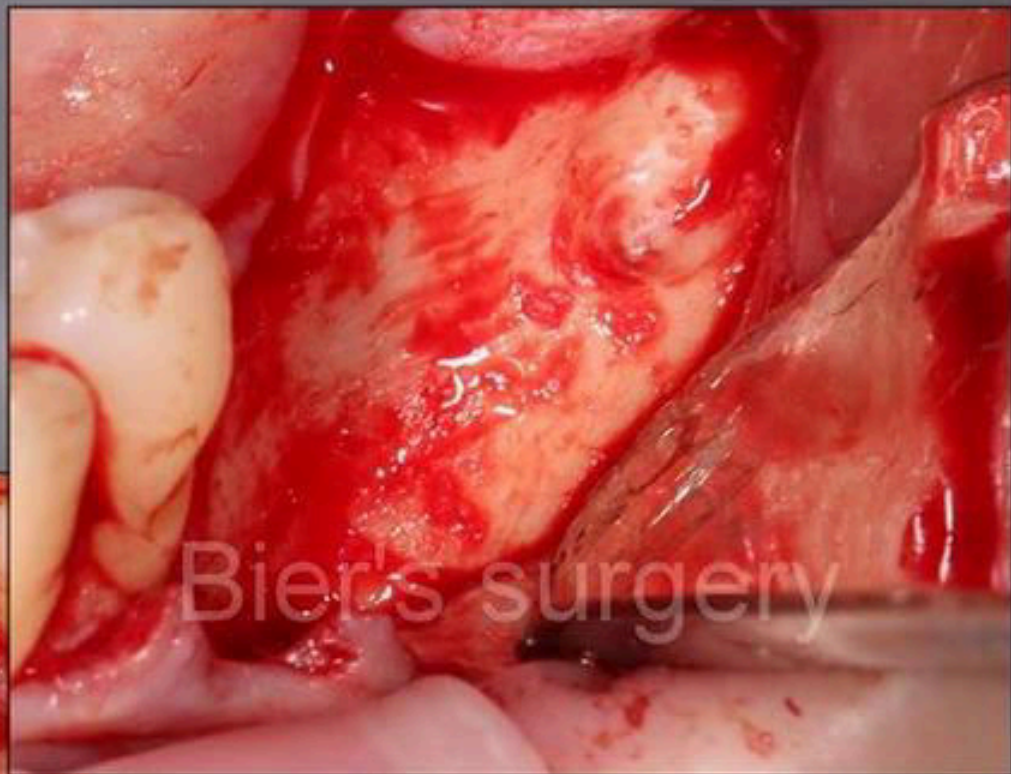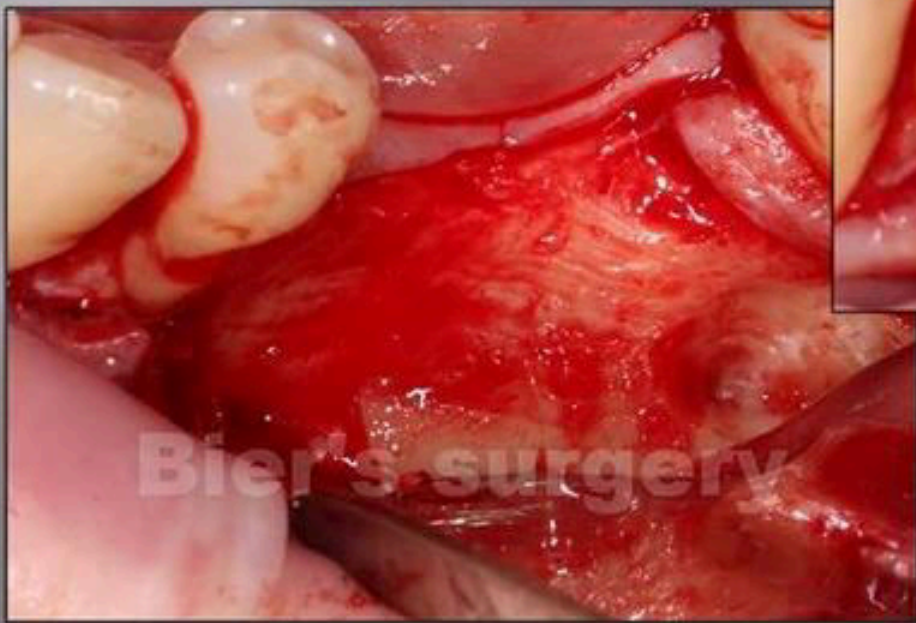
## Case 2.

Patient Z. 52 years  
old. Atrophy  
of the alveolar crest.



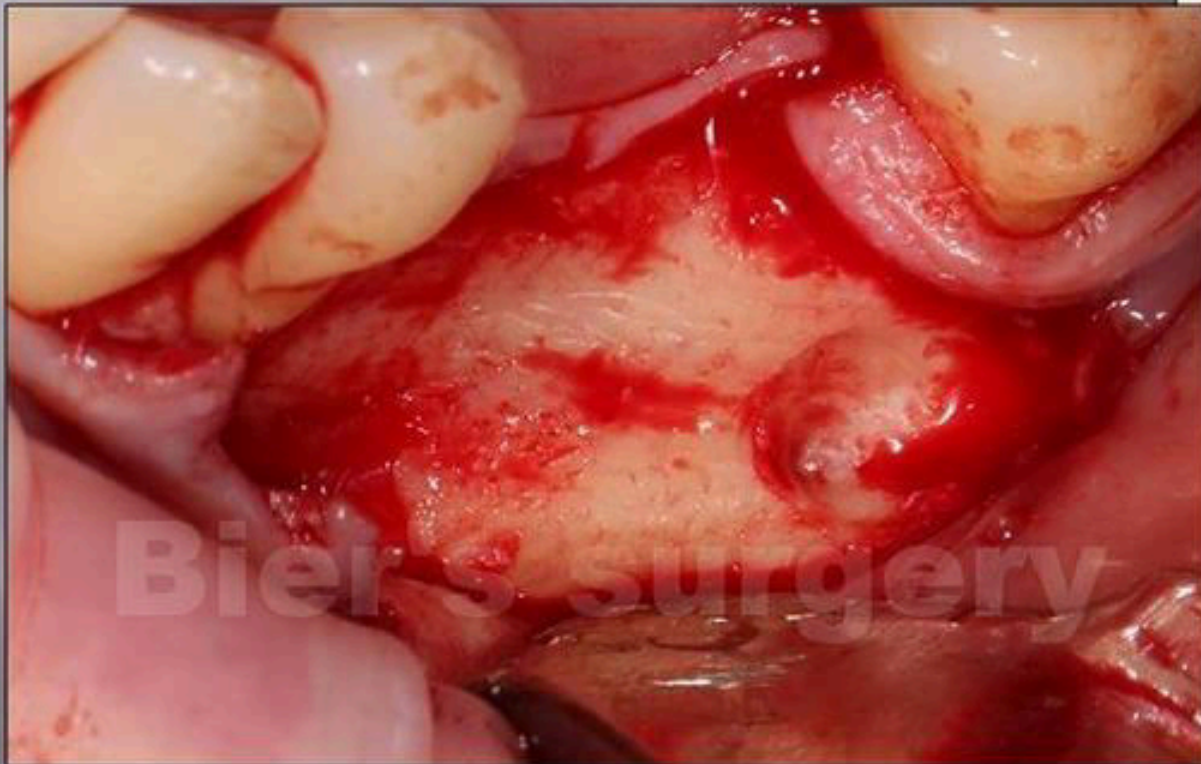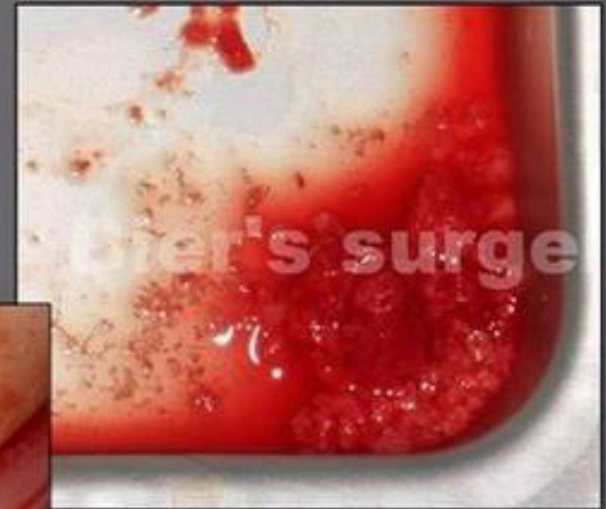## Case 2.

Open recipient and...  
donor site



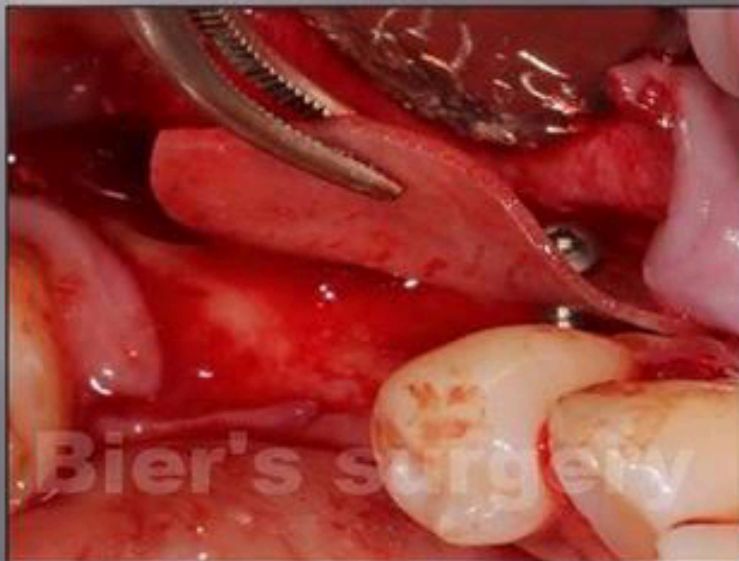
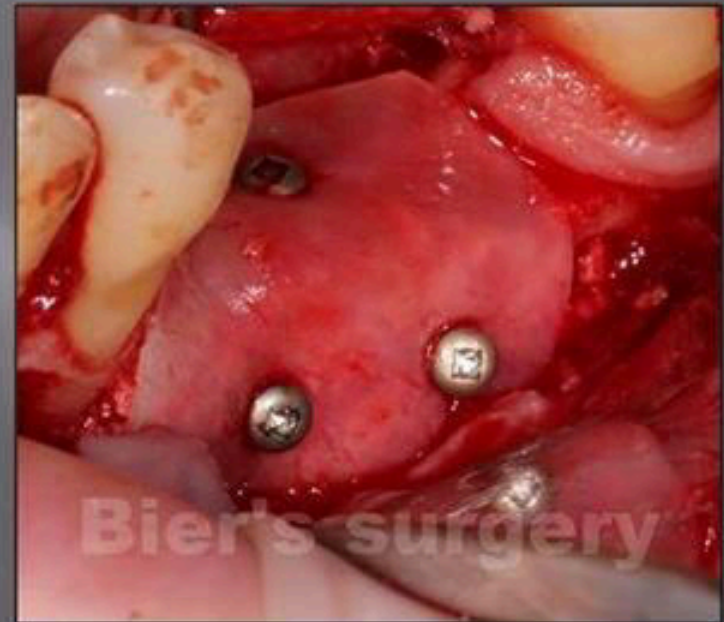
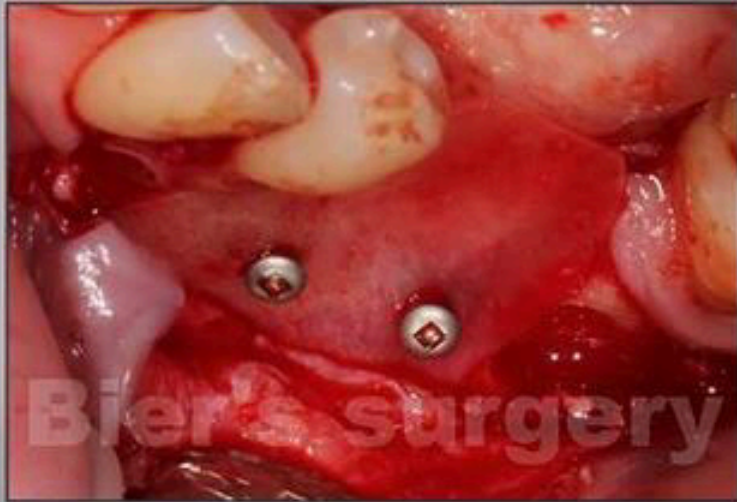## Case 2.

Autogenous bone  
harvesting and recipient  
site preparation



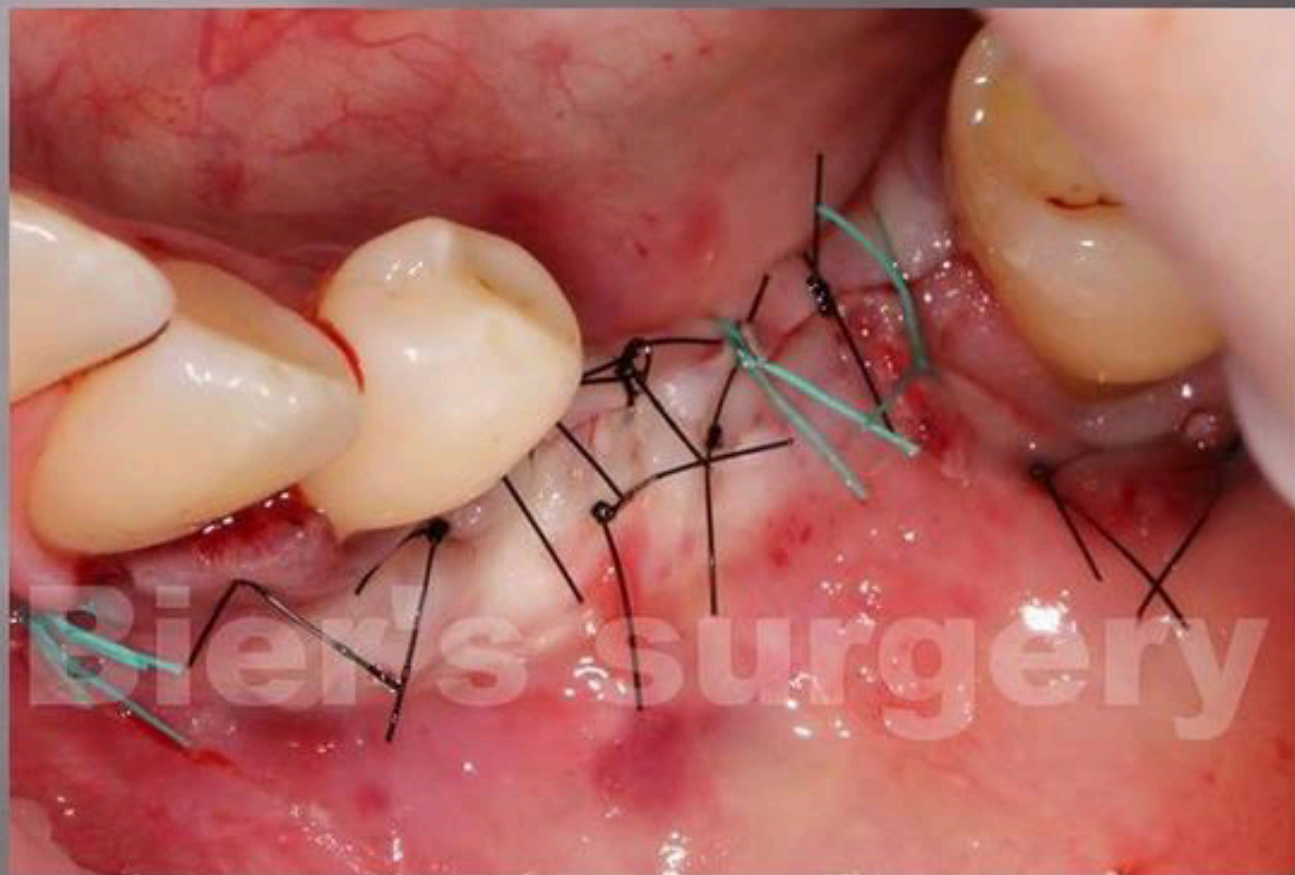## Case 2.

Mounting lamina and  
grafting



## Case 2.

### Suturing



Case 2.

After 5 month

## Case 2.

After 5 month.

